ORIGINAL ARTICLE

The role of repeated extended FAST in patients with stable blunt thoracoabdominal trauma

Mümin Murat Yazıcı, M.D.[1] **Özcan Yavaşi, M.D.**[2], **Ali Çelik, M.D.**[2] **Gürkan Altuntaş, M.D.**[2] **Mehmet Altuntaş, M.D.**[2] **Özlem Bilir, M.D.**[2] **Gökhan Ersunan, M.D.**[2]

[1]Department of Emergency Medicine, Kaçkar State Hospital, Rize-*Türkiye*

[2]Department of Emergency Medicine, Recep Tayyip Erdoğan University Training and Research Hospital, Rize-*Türkiye*

ABSTRACT

BACKGROUND: Thoracic and abdominal computed tomography scans are widely used modalities for trauma patients in emergency department (ED). However, alternative diagnostic and follow-up tools are also needed, due to limitations such as high cost and excessive radiation exposure. This study aimed to investigate the utility of repeated extended focused abdominal sonography for trauma (rE-FAST) performed by the emergency physician in patients with stable blunt thoracoabdominal trauma.

METHODS: This was a prospective, single-center diagnostic accuracy study. Patients with blunt thoracoabdominal trauma admitted to the ED were included in the study. The E-FAST was performed on the patients included in the study at the 0th h, the 3rd h, and the 6th h during their follow-up. Then, the diagnostic accuracy metrics of E-FAST and rE-FAST were calculated.

RESULTS: The sensitivity and specificity of E-FAST in determining thoracoabdominal pathologies were found to be 75% and 98.7%, respectively. The sensitivity and specificity for specific pathologies were 66.7% and 100% for pneumothorax, 66.7% and 98.8% for hemothorax, and 66.7% and 100% for hemoperitoneum, respectively. The sensitivity and specificity of rE-FAST in determining thoracal and/or abdominal hemorrhage in stable patients were found to be 100% and 98.7%, respectively.

CONCLUSION: E-FAST successfully rules in thoracoabdominal pathologies in patients with blunt trauma, with its high specificity. However, only a rE-FAST might be sensitive enough to exclude traumatic pathologies in these stable patients.

Keywords: Emergency ultrasound; point-of-care ultrasound; repeated extended focused abdominal sonography for trauma; trauma; ultrasonography.

INTRODUCTION

Trauma patients constitute a significant portion of admissions to emergency department (ED), and trauma-related deaths rank first among young people.[1,2] Computed tomography (CT) is the reference imaging method for patients admitted to ED after blunt thoracoabdominal trauma.[3] CT is expensive and exposes patients to excessive radiation, limiting its access and further highlighting the need for alternative diagnostic methods, especially in hemodynamically stable patients.[4,5] In this regard, ultrasonography (USG) is stated as a safe and readily available tool without radiation exposure in many ED. Previous studies showed that USG could be useful in detecting traumatic thoracoabdominal pathologies such as hemoperitoneum, hemothorax, pneumothorax, pericardial effusion, and chest wall injuries.[6-11]

The use of focused abdominal sonography for trauma (FAST) protocol and its extension to thorax (extended FAST) was initiated in the 1990s, and today, those are actively used as a part of physical examination in trauma patients.[9,12] However, their use provides benefits only for patients with a positive USG because of lacking enough sensitivity.[8-10,13-15] Hence, the

Cite this article as: Yazıcı MM, Yavaşi O, Çelik A, Altuntaş G, Altuntaş M, Bilir O, Ersunan G. The role of repeated extended FAST in patients with stable blunt thoracoabdominal trauma. Ulus Travma Acil Cerrahi Derg 2023;29:553-559.

Address for correspondence: Mümin Murat Yazıcı, M.D.
Department of Emergency Medicine, Kaçkar State Hospital, Rize, Türkiye
E-mail: mmuratyazici53@gmail.com

Ulus Travma Acil Cerrahi Derg 2023;29(5):553-559 DOI: 10.14744/tjtes.2022.93529 Submitted: 25.10.2021 Revised: 16.11.2022 Accepted: 14.12.2022
OPEN ACCESS This is an open access article under the CC BY-NC license (http://creativecommons.org/licenses/by-nc/4.0/).

utility of repeated FAST examination performed by clinicians (surgeons or emergency physicians [EP]) and radiologists was studied, indicating better diagnostic performance.[6,16] Conversely, the utility of repeated extended FAST (rE-FAST) examination performed by EPs is a less studied issue.

The management of thoracoabdominal trauma is mostly determined clinically in combination with other clinical findings, because routine laboratory tests are generally of limited value and physical examination may be unreliable in some cases. At the same time, there is not a consensus for a safe period of observation of trauma patients. Hence, we thought that we need a reliable, inexpensive, and non-invasive diagnostic instrument with high sensitivity and specificity, mainly in diagnosing and following the pathologies of patients with stable blunt trauma. Therefore, the present study was designed to determine the diagnostic value of the rE-FAST in the diagnosis of thoracoabdominal pathology and its utility in the follow-up of blunt thoracoabdominal trauma.

MATERIALS AND METHODS

Study Design and Setting

This prospective, observational, and single-center diagnostic accuracy study was conducted in a tertiary academic ED between July and September 2019. Based on our hypothesis for E-FAST to be an accurate tool in managing patients without CT scans, the sensitivity and specificity should be at least 97–98% compared to CT (100%). In this regard, 85 patients (final sample size: 76 and 10% dropout: 85) were needed to reach this objective with a 95% confidence interval, with an expected dropout rate of 10%, and a predicted disease prevalence of 10%. Approval from the local ethics committee (Decision No: 2019/104) was obtained before patients' enrollments.

Patient Selection and Data Collection

All patients admitted to the ED with blunt thoracoabdominal trauma, aged 18 years or older, having clinical findings on physical examination, and not meeting the exclusion criteria were included in the study. Pregnant patients, patients with trauma in anatomical regions other than thoracoabdominal trauma that causes hemodynamic compromise, patients who could not continue to be followed up due to emergency laparotomy or thoracotomy, patients under 18 years of age, patients in whom CT could not be performed, patients with a disease known to cause false positives (pleural effusion, pericardial effusion, ascites), and patients withdrawing consent were excluded from the study. The study flowchart is shown in Fig. 1.

Study Protocol

The primary evaluation, clinical, laboratory follow-up, and treatment of the patient in the ED were performed by the EP

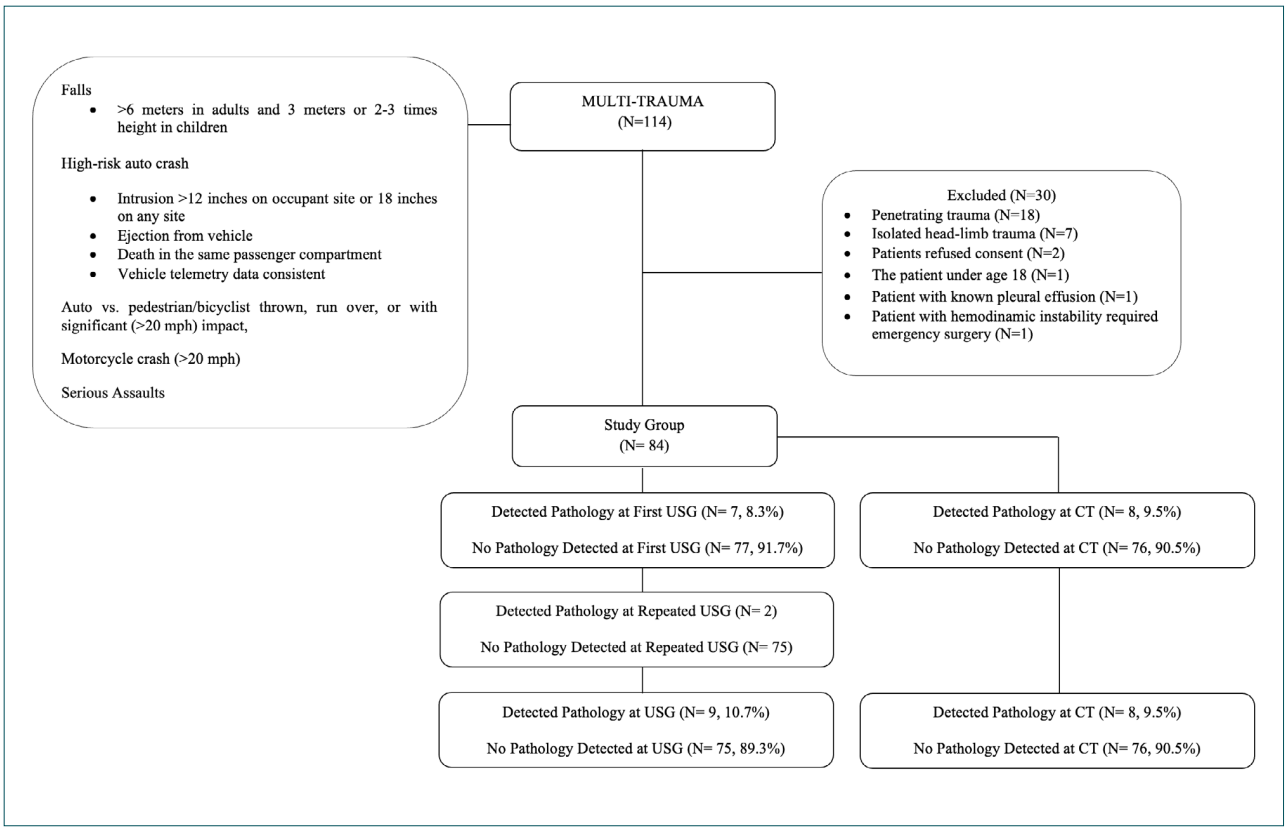

Figure 1. Study flowchart

on duty. The primary physician recorded all vital and physical examination findings of the patients at admission to the ED (0th h), 3rd h, and 6th h. The patients' diagnoses and treatment were supplied according to the current Advanced Trauma Life Support guidelines. The USG examinations of the patients were performed by two emergency medicine attending physicians and two senior emergency medicine residents who were not responsible for the primary care of the patients. They participated in the USG courses (basic and advanced USG courses) and were certified by relevant professional emergency medicine associations.

The sonographers were blinded to the laboratory parameters, vital signs, and other imaging findings. As per our routine practice, for all blunt trauma patients who needed CT imaging, contrast-enhanced thorax and abdominal CT were performed by injecting intravenous contrast at a dose of 1 mg/kg. These CTs were evaluated and reported by radiology experts. Emergency medicine physicians and residents conducted the trauma follow-up. The decision of hospitalization, discharge, or emergency operation was given together with the trauma team physicians according to vital signs, laboratory findings, imaging results, and clinical status.

E-FAST Protocol

The sonographic examination was performed with a Fujifilm-Sonosite-FC1 (FUJIFILM SonoSite, Inc., Bothell, WA 98021 USA, 2015) model USG device. A high-resolution 7–12 MHz linear transducer and a low-resolution 3.5–5 MHz convex transducer were used for the thorax. A low-resolution 3.5–5 MHz convex transducer was used for the abdomen. The thorax examination was performed with a 7–12 MHz linear transducer for the detection of pneumothorax over three lines: the midclavicular, anterior axillary, and posterior axillary lines. Then, a 3.5–5 MHz convex transducer was used to investigate the hemothorax and contusion. According to the FAST protocol, the abdomen was evaluated in terms of the hemoperitoneum and hemopericardium using a 3.5–5 MHz convex transducer. The USG examination performed at the time of admission (0th h) was repeated at the 3rd and 6th h and recorded.

Statistical Analysis

All statistical analysis were conducted using IBM SPSS Statistics v.22 and Jamovi v.1.6 Statistics package programs (IBM SPSS Statistics for Windows, Version 22.0. Armonk, NY: IBM Corp. – The Jamovi Project (2021) Computer Software, Version 1.6. Sydney, Australia). In our study, type I errors were accepted as 5% for all comparisons. Continuous variables were described as median and interquartile range (IQR). Categorical data were represented as frequency (n) and percentage (%). Contingency tables were organized for diagnostic test statistics of E-FAST and rE-FAST in reference to CT. Then, sensitivity, specificity, likelihood ratios (+LR, −LR), positive predictive value, and negative predictive value with 95% confidence intervals (95% CI) were calculated for E-FAST and rE-FAST. STARD 2015 guidelines for diagnostic accuracy studies were followed while conducting this study.[17]

RESULTS

Evaluation of Clinical and Demographic Features

Throughout the study period, a total of 30 patients (penetrating trauma [n=18], isolated head-limb trauma [n=7], patients refused consent [n=2], the patient under age 18 [n=1], patient with known pleural effusion [n=1], and patient with hemodynamic instability required emergency surgery [n=1]) with multi-trauma were excluded from the study group because they met at least one exclusion criterion. Finally, the study group consisted of 84 patients with blunt thoracoabdominal trauma. Of the 84 patients, 56 (66.7%) were male, and 28 (33.3%) were female. The patients were aged between 19 and 89 (median: 50, IQR: 36–65). The mechanisms of trauma were 39 (46.4%) motor vehicle accidents, 35 (41.7%) falls, 4 (4.8%) assaults, 3 (3.6%) bicycle accidents, and 3 (3.6%) falling on objects. The demographic data and trauma mechanisms of the patients are summarized in Table 1.

Evaluation of USG in the Study Population

In E-FAST examination of the 0th h, pneumothorax was detected in four patients, hemothorax in three patients, and hemoperitoneum in two patients. One more pneumothorax, one more hemothorax, and one more hemoperitoneum were detected during follow-up, and no hemopericardium was detected in any of the patients. The specific findings are summarized in Table 2.

Table 1. The patients' demographic data and trauma mechanisms

Demographic data and trauma mechanisms	All patients (n=84) (%)
Gender	
Male	56 (66.7)
Female	28 (33.3)
Age	
(Year)	50 (IQR 36–65)
Mechanisms of trauma	
Motor vehicle accident	39 (46.4)
Fall	35 (41.7)
Assaults	4 (4.8)
Bicycle accidents	3 (3.6)
Falling on objects	3 (3.6)

IQR: Interquartile range; Normally distributed data are expressed as Mean±SD (Min.-Max.); Abnormally distributed data as median (IQR 25–75)

Table 2. Numbers of specific findings detected by E-FAST and repeated E-FAST

Findings	True positive (TP)	False negative (FN)	False positive (FP)	True negative (TN)
0th-h E-FAST				
Any pathology	6	2	1	75
Any hemorrhage	4	1	1	78
Pneumothorax	4	2	0	78
Hemothorax	2	1	1	80
Hemoperitoneum	2	1	0	81
Repeated E-FAST				
Any pathology	8	0	1	75
Any hemorrhage	5	0	1	78
Pneumothorax	5	1	0	78
Hemothorax	3	0	1	80
Hemoperitoneum	3	0	0	81
CT				
Any pathology	8	0	0	76
Any hemorrhage	5	0	0	79
Pneumothorax	6	0	0	78
Hemothorax	3	0	0	81
Hemoperitoneum	3	0	0	81

CT: Computed tomography; any hemorrhage; hemoperitoneum and/or hemothorax.

Table 3. Diagnostic accuracy metrics of E-FAST and repeated E-FAST

Diagnostic metrics	Any pathology	Hemorrhage*	Pneumothorax	Hemothorax	Hemoperitoneum
0th-h E-FAST^					
Sensitivity	75.0 (34.9–96.8)	80.0 (28.4–99.5)	66.7 (22.3–95.7)	66.7 (09.4–99.1)	66.7 (09.4–99.1)
Specificity	98.7 (92.9– 100)	98.7 (93.2– 100)	100 (95.4–100)	98.8 (93.3–100)	100 (95.6–100)
PPV	85.7 (45.1–97.8)	80.0 (35.2–96.7)	100	66.7 (19.6–94.3)	100
NPV	97.4 (91.9–99.2)	98.7 (93.1–99.8)	97.5 (92.6–99.1)	98.8 (94.2–99.8)	98.8 (94.2–99.8)
+LR	57 (7.8–416.0)	63.2 (8.6–465.2)	∞	54 (6.6–443.5)	∞
−LR	0.25 (0.08–0.83)	0.20 (0.03–1.15)	0.33 (0.11–1.02)	0.34 (0.07–1.68)	0.33 (0.07–1.63)
Accuracy	96.4 (89.9–99.2)	97.6 (91.7–99.7)	97.6 (91.7–99.7)	97.6 (91.7–99.7)	98.8 (93.5–100)
Repeated E-FAST^					
Sensitivity	100 (63.0–100)	100 (63.0–100)	83.3 (35.9–99.6)	100 (29.2–100)	100 (29.2–100)
Specificity	98.7 (92.9–100)	98.7 (93.2–100)	100 (95.4–100)	98.8 (93.3–100)	100 (95.6–100)
PPV	88.9 (53.3–98.3)	88.3 (41.4–97.2)	100	75.0 (30.0–96.0)	100
NPV	100	100	98.7 (92.9–99.8)	100	100
+LR	76 (10.9–532.6)	79 (11.3–553.9)	∞	81 (11.6–568.1)	∞
−LR	0	0	0.17 (0.03–1.02)	0	0
Accuracy	98.8 (93.5–100)	98.8 (93.5–100)	99.8 (93.5–100)	99.8 (93.5–100)	100 (95.7–100)

LR: Likelihood ratio; PPV: Positive predictive value; NPV: Negative predictive value; CI: Confidence interval; Hemorrhage*: Any hemorrhage (hemoperitoneum and/or hemothorax); ^: Metric (95% CI); ∞: Infinity.

In detecting thoracoabdominal pathologies, E-FAST had a sensitivity of 75% and a specificity of 98.7% compared to CT for any type of injury. Specifically, E-FAST was 66.7% sensitive and 100% specific for pneumothorax, 66.7% sensitive and 98.8% specific for hemothorax, and 66.7% sensitive and 100% specific for hemoperitoneum. The sensitivity and specificity of rE-FAST in determining hemorrhage in stable patients were found to be 100% and 98.7%, respectively. Specifically, rE-FAST was 83.3% sensitive and 100% specific for pneumothorax, 100% sensitive and 98.8% specific for hemothorax, and 100% sensitive and 100% specific for hemoperitoneum. The diagnostic values of the 0th-h E-FAST and follow-up rE-FAST of the patients included in the study are presented in Table 3.

DISCUSSION

Given the importance of diagnosing thoracic and abdominal pathologies after blunt trauma, many cases are diagnosed with CT.[3] However, the need for alternative diagnosis and follow-up tools, especially in hemodynamically stable patients, has led us to a search for alternatives to CT. For the management of trauma patients, anamnesis, physical examination, vital signs, laboratory results, and imaging methods are evaluated in combination.[18]

In thoracoabdominal trauma, USG is used as a part of the physical examination using the E-FAST protocol.[12,19] In a recent study of Akoglu et al., the diagnostic accuracy of E-FAST in reference to CT was compared. E-FAST had a sensitivity of 42.9%, and a specificity of 98.4%, in terms of detecting any pathology that emphasized the usefulness of E-FAST in diagnosis rather than excluding pathologies.[13] In a novel meta-analysis, the accuracy of E-FAST in detecting thoracoabdominal pathologies was investigated. In 24,350 trauma cases, E-FAST had a sensitivity of 69% and a specificity of 99% for pneumothorax; sensitivity of 91% and specificity of 94% for pericardial effusion; sensitivity of 74% and specificity of 98% for intra-abdominal free fluid; and sensitivity of 74% and specificity of 95% for intra-abdominal fluid, respectively.[14] In addition, a recent Cochrane review that included 8635 cases investigated the diagnostic accuracy of bedside USG in diagnosing thoracoabdominal injuries (sensitivity: 74%, specificity: 96%) in patients with blunt trauma.[20] As a result of these reports, it was concluded that positive E-FAST can help guide treatment decisions. However, a negative E-FAST examination did not rule out injuries and should be confirmed by a reference test such as CT.[13,14,20] In our study, we observed almost similar diagnostic performance of 0th-h E-FAST with poor sensitivity and high specificity that showed the poor power of single E-FAST examination to exclude thoracoabdominal pathologies.

Mohammadi and Ghasemi-Rad reviewed the role of repeated USG by gastrointestinal injury in patients with blunt abdominal trauma. In those with isolated gastrointestinal injury, the sensitivity of FAST was 38.5%, and the sensitivity of repeated USG in negative initial FAST patients in the detection of gastrointestinal injury was 85.2% in 1550 trauma cases. As a result of the study, it was concluded that repeated USG can facilitate the diagnosis of gastrointestinal tract injury and can be an effective method instead of CT in developing countries.[21] Similarly, a prospective study including 307 FAST examinations suggested that a secondary examination significantly increases the accuracy in detecting hemoperitoneum.[16] In our study, we observed that the power of a repeated E-FAST in excluding thoracoabdominal pathologies advanced.

Davoodabadi et al. reviewed the diagnostic value of serial ultrasound in blunt abdominal trauma. A total of 125 trauma patients were evaluated for the diagnostic value of the repeated ultrasound in the diagnosis of free intraperitoneal fluid. The sensitivity of ultrasound at presentation, 12 h, and 24 h was 19.8%, 75.2%, and 82.2%, respectively, showing an increasing pattern with repeated ultrasound examinations.[22] In our study, the sensitivity and specificity of rE-FAST in determining any hemorrhage in stable patients were found to be 100% (from 80%) and 98.7%, respectively. Likewise, rE-FAST had a sensitivity of 100% (from 66.7%) and a specificity of 98.8% for hemothorax, a sensitivity of 100% (from 66.7%), and a specificity of 100% for hemoperitoneum. These results showed the diagnostic contribution of repeated USG in excluding thoracoabdominal hemorrhage compared to a single USG.

The main purpose of this study was to investigate the utility of rE-FAST in stable patients with thoracoabdominal trauma. In previous literature, we could not find enough study on this issue. Bahrami-Motlagh et al. compared the examination findings, initial USG, and repeated USG in children with blunt abdominal trauma. The results indicated that the addition of initial USG and repeated USG had sufficient sensitivity and specificity for detecting intra-abdominal pathologies, thus suggesting the use of USG to reduce CT scans for intra-abdominal pathologies.[6] In our study, the sensitivity and specificity of rE-FAST in determining any pathology in stable patients were found to be 100% (from 75%) and 98.7%, respectively. Furthermore, rE-FAST had a sensitivity of 83.3% (from 66.7%) and a specificity of 100% for pneumothorax. These findings showed the diagnostic contribution of repeated USG in diagnosing and excluding thoracoabdominal pathology compared to a single USG.

The primary and real-world limitation of this study and similar studies is the user dependence on ultrasound. Although this limitation generally poorly succeeds in excluding pathology, the success rate increases in concluding the existence of pathology. The relatively small sample size was the second important limitation of this study. However, we reached the sample size that was calculated prior to patient enrollment. Hence, we do not think that this limitation effected our results.

Conclusion

The findings of this study suggest that even a single E-FAST successfully rules in thoracoabdominal pathologies in patients with blunt trauma, with its high specificity. However, only a repeated E-FAST is sensitive enough to exclude traumatic pathologies. Further prospective studies designed to validate our results are needed to generalize and incorporate them into clinical practice.

Ethics Committee Approval: This study was approved by the Recep Tayyip Erdoğan University Training and Research Hospital Clinical Research Ethics Committee (Date: 16.07.2019, Decision No: 40465587-050.01.04-178

Peer-review: Externally peer-reviewed.

Authorship Contributions: Concept: Ö.Y., M.M.Y.; Design: Ö.Y., M.M.Y.; Supervision: Ö.Y., M.A., G.A., Ö.B., A.Ç., G.E.; Materials: Ö.Y., M.M.Y., A.Ç.; Data: Ö.Y., M.M.Y., A.Ç., G.A.; Analysis: Ö.Y., M.M.Y., A.Ç.; Literature search: Ö.Y., M.M.Y., A.Ç.; Writing: Ö.Y., M.M.Y., A.Ç.; Critical revision: Ö.Y., M.A., G.E., Ö.B., A.Ç., G.A., M.M.Y.

Conflict of Interest: None declared.

Financial Disclosure: The authors declared that this study has received no financial support.

REFERENCES

1. Kirkpatrick AW, Ball CG, D'Amours SK, Zygun D. Acute resuscitation of the unstable adult trauma patient: Bedside diagnosis and therapy. Can J Surg 2008;51:57–69.
2. Tintinalli JE, Stapczynski JS, Ma OJ, Cline D, Meckler GD, Yealy DM. Tintinalli's Emergency Medicine: A Comprehensive Study Guide. New York: McGraw-Hill Education; 2016.
3. Salim A, Sangthong B, Martin M, Brown C, Plurad D, Demetriades D. Whole body imaging in blunt multisystem trauma patients without obvious signs of injury: Results of a prospective study. Arch Surg 2006;141:468–73; discussion 73–5. [CrossRef]
4. Beatty L, Furey E, Daniels C, Berman A, Tallon JM. Radiation exposure from CT scanning in the resuscitative phase of trauma care: A level one trauma centre experience. CJEM 2015;17:617–23. [CrossRef]
5. Brenner DJ, Hall EJ. Computed tomography--an increasing source of radiation exposure. N Engl J Med 2007;357:2277–84. [CrossRef]
6. Bahrami-Motlagh H, Hajijoo F, Mirghorbani M, SalevatiPour B, Haghighimorad M. Test characteristics of focused assessment with sonography for trauma (FAST), repeated FAST, and clinical exam in prediction of intra-abdominal injury in children with blunt trauma. Pediatr Surg Int 2020;36:1227–34. [CrossRef]
7. Çelik A, Akoglu H, Omercikoglu S, Bugdayci O, Karacabey S, Kabaroglu KA, et al. The diagnostic accuracy of ultrasonography for the diagnosis of rib fractures in patients presenting to emergency department with blunt chest trauma. J Emerg Med 2021;60:90–7. [CrossRef]
8. Kozaci N, Avci M, Ararat E, Pinarbasili T, Ozkaya M, Etli I, et al. Comparison of ultrasonography and computed tomography in the determination of traumatic thoracic injuries. Am J Emerg Med 2019;37:864–8.
9. Montoya J, Stawicki SP, Evans DC, Bahner DP, Sparks S, Sharpe RP, et al. From FAST to E-FAST: An overview of the evolution of ultrasound-based traumatic injury assessment. Eur J Trauma Emerg Surg 2016;42:119–26. [CrossRef]
10. Zieleskiewicz L, Fresco R, Duclos G, Antonini F, Mathieu C, Medam S, et al. Integrating extended focused assessment with sonography for trauma (eFAST) in the initial assessment of severe trauma: Impact on the management of 756 patients. Injury 2018;49:1774–80. [CrossRef]
11. Akdemir HU, Caliskan F, Kati C, Baydin A. The blunt abdominal trauma bedside ultrasonography comparison with trauma severity scores and computerized tomography. J Coll Physicians Surg Pak 2019;29:621–5.
12. Bode PJ, Edwards MJ, Kruit MC, van Vugt AB. Sonography in a clinical algorithm for early evaluation of 1671 patients with blunt abdominal trauma. AJR Am J Roentgenol 1999;172:905–11. [CrossRef]
13. Akoglu H, Celik OF, Celik A, Ergelen R, Onur O, Denizbasi A. Diagnostic accuracy of the extended focused abdominal sonography for trauma (E-FAST) performed by emergency physicians compared to CT. Am J Emerg Med 2018;36:1014–7. [CrossRef]
14. Netherton S, Milenkovic V, Taylor M, Davis PJ. Diagnostic accuracy of eFAST in the trauma patient: A systematic review and meta-analysis. CJEM 2019;21:727–38. [CrossRef]
15. Matsushima K, Frankel HL. Beyond focused assessment with sonography for trauma: Ultrasound creep in the trauma resuscitation area and beyond. Curr Opin Crit Care 2011;17:606–12. [CrossRef]
16. Kanafi AR, Giti M, Gharavi MH, Alizadeh A, Pourghorban R, Shekarchi B. Diagnostic accuracy of secondary ultrasound exam in blunt abdominal trauma. Iran J Radiol 2014;11:e21010. [CrossRef]
17. Prager R, Bowdridge J, Kareemi H, Wright C, McGrath TA, McInnes MD. Adherence to the standards for reporting of diagnostic accuracy (STARD) 2015 guidelines in acute point-of-care ultrasound research. JAMA Netw Open 2020;3:e203871. [CrossRef]
18. American College of Surgeons. Committee on Trauma: Advanced Trauma Life Support for Doctors, Student Course Manual. 10th ed. Chicago: American College of Surgeons; 2018.
19. Kornezos I, Chatziioannou A, Kokkonouzis I, Nebotakis P, Moschouris H, Yiarmenitis S, et al. Findings and limitations of focused ultrasound as a possible screening test in stable adult patients with blunt abdominal trauma: A Greek study. Eur Radiol 2010;20:234–8. [CrossRef]
20. Stengel D, Leisterer J, Ferrada P, Ekkernkamp A, Mutze S, Hoenning A. Point-of-care ultrasonography for diagnosing thoracoabdominal injuries in patients with blunt trauma. Cochrane Database Syst Rev 2018;12:CD012669. [CrossRef]
21. Mohammadi A, Ghasemi-Rad M. Evaluation of gastrointestinal injury in blunt abdominal trauma "FAST is not reliable": The role of repeated ultrasonography. World J Emerg Surg 2012;7:2. [CrossRef]
22. Davoodabadi A, Marzban F, Ghafoor L, Talari HR, Abdolrahim-Kashi E, Akbari H, et al. Diagnostic value of serial ultrasound in blunt abdominal trauma. Arch Trauma Res 2017;6:e44176. [CrossRef]

ORİJİNAL ÇALIŞMA - *ÖZ*

Stabil künt torakoabdominal travmalı hastalarda tekrarlanan E-FAST'ın rolü

Dr. Mümin Murat Yazıcı,[1] Dr. Özcan Yavaşi,[2] Dr. Ali Çelik,[2] Dr. Gürkan Altuntaş,[2] Dr. Mehmet Altuntaş,[2] Dr. Özlem Bilir,[2] Dr. Gökhan Ersunan[2]

[1]Kaçkar Devlet Hastanesi, Acil Tıp Kliniği, Rize

[2]Recep Tayyip Erdoğan Üniversitesi Eğitim ve Araştırma Hastanesi, Acil Tıp Kliniği, Rize

AMAÇ: Torakal ve abdominal bilgisayarlı tomografi taramaları acil serviste travma hastaları için yaygın olarak kullanılmaktadır. Bununla birlikte, yüksek maliyet, aşırı radyasyon maruziyeti gibi sınırlamalar nedeniyle alternatif tanı ve takip araçlarına da ihtiyaç vardır. Bu çalışma, stabil künt torakoabdominal travması olan hastalarda acil hekimi tarafından yapılan travma için tekrarlanan genişletilmiş odaklanmış abdominal sonografinin (rE-FAST) yararlarını araştırmayı amaçlamıştır.

GEREÇ VE YÖNTEM: Bu prospektif, tek merkezli tanısal doğruluk çalışmasıydı. Künt torakoabdominal travma sonrası acil servise başvuran hastalar çalışmamıza dahil edildi. Çalışmaya alınan hastalara gelişinde (0'ıncı saatte) ve takipleri sırasında 3'üncü ve 6'ncı saatte E-FAST yapıldı. E-FAST ve rE-FAST tanısal doğruluk ölçümleri hesaplandı.

BULGULAR: Torakoabdominal patolojilerin belirlenmesinde E-FAST'in duyarlılığı ve özgüllüğü sırasıyla %75 ve %98,7 olarak bulunmuştur. Spesifik patolojiler için duyarlılık ve özgüllük pnömotoraks için sırasıyla %66.7 ve %100, hemotoraks için %66.7 ve %98.8, hemoperitoneum için %66.7 ve %100'idi. Stabil hastalarda torakal ve/veya abdominal kanamanın belirlenmesinde rE-FAST'ın duyarlılığı ve özgüllüğü sırasıyla %100 ve %98.7 olarak bulunmuştur.

TARTIŞMA: E-FAST, yüksek özgüllüğü ile künt travmalı hastalarda torakoabdominal patolojilere başarıyla tanı koyabilir. Bununla birlikte, stabil hastalarda ancak rE-FAST travmatik patolojileri dışlamak için yeterli duyarlılığa sahiptir.

Anahtar sözcükler: Acil ultrasound; hedef odaklı ultrason; tekrarlanan E-FAST; travma; ultrasonografi.

Ulus Travma Acil Cerrahi Derg 2023;29(5):553-559 doi: 10.14744/tjtes.2022.93529